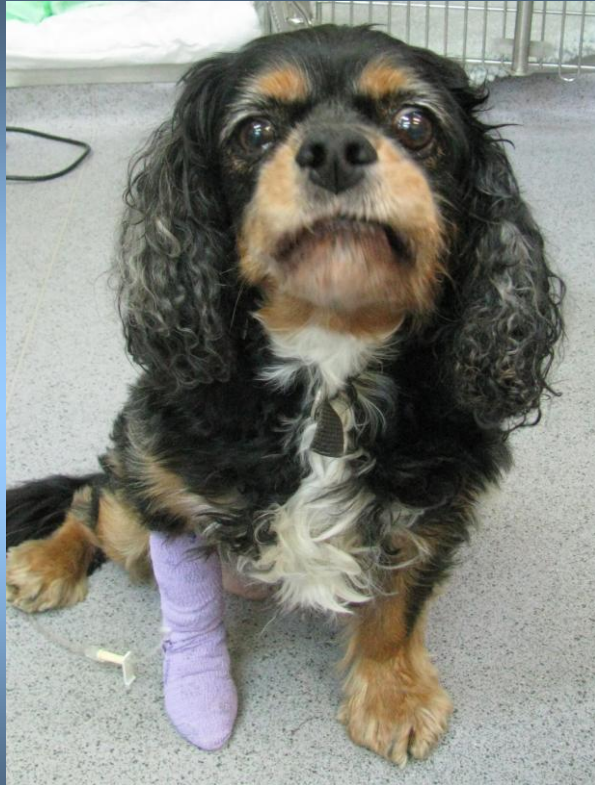





# April



Tina is a 10 year old Cavalier King Charles Spaniel. Her owners called the out of hours emergency service in February. Tina had swallowed a whole potato and started choking.

Carole the vet on duty advised that Tina should be seen at the surgery. On clinical examination Tina was distressed and having difficulty breathing. Carole could not see any obvious foreign body in Tina's mouth or upper oesophagus (the muscular tube which carries food from the mouth to the stomach). Tina was admitted for further investigations.

Tina needed a general anaesthetic and x-rays. The x-rays revealed that the potato was present in the oesophagus. It was located near to the stomach entrance and also near to the heart. The potato was pushing on the heart and making it difficult for Tina to breathe.

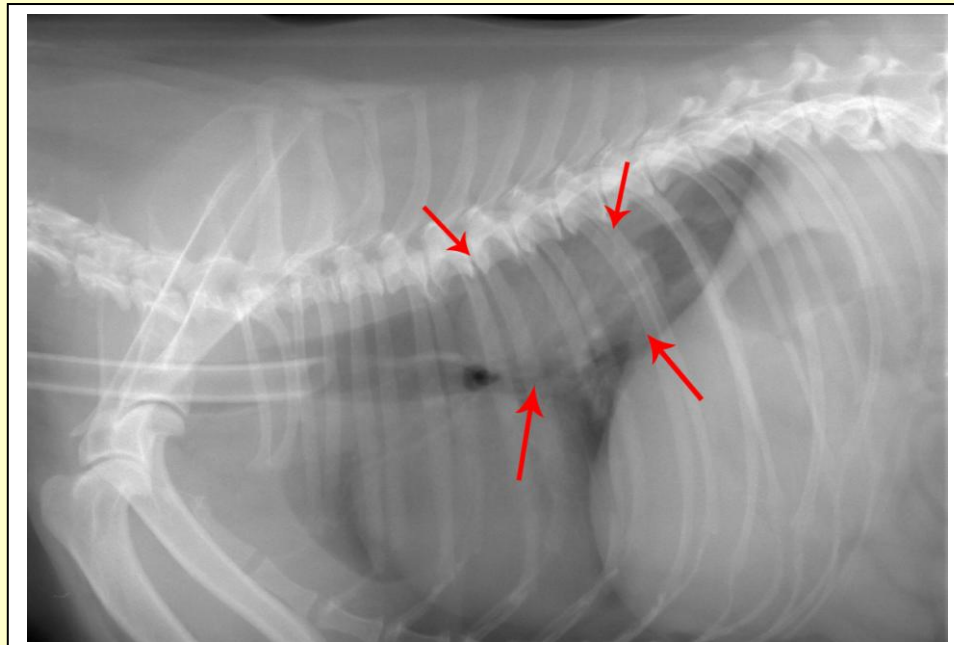


The vet attempted to move the potato in to the stomach using an endoscope, but it was firmly lodged in place. Surgical intervention was required. Carole made an incision into the abdomen and then through the diaphragm into the chest. The potato was massaged in to the stomach and was then removed from the stomach.

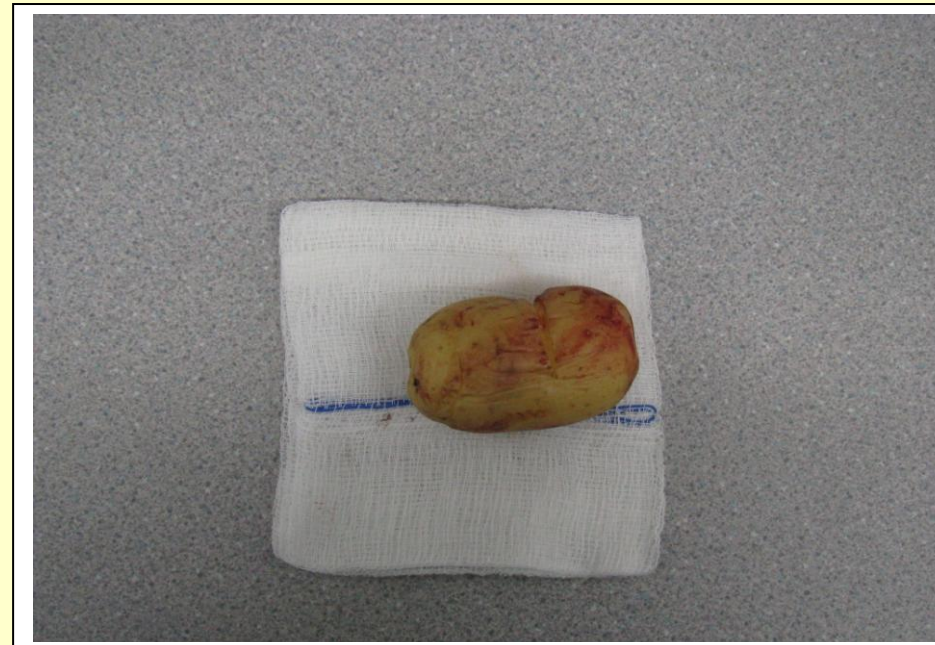This is much simpler than removal from the oesophagus.

Following her operation Tina was kept in overnight. She made a good recovery and was able to go home the following morning. Ten days after the operation Carole removed the stitches from Tina's wound.

# The story in pictures...



The x-ray showing the potato in the oesophagus



The potato after it was surgically removed

Tina was kept in overnight following her operation. She made a good recovery and was able to go home the following morning. The stitches were removed ten days after the operation and Tina is doing very well.

## What is a foreign body?

- An object originating from outside the body.
- Common in dogs.
- They usually require surgical intervention.
- They may be fatal

## Types of foreign body?

**Oral:** Sticks or bones can become wedged between the back teeth. Signs include pawing at the mouth, drooling, bleeding from the mouth and smelly breath.

**Respiratory:** Foreign bodies can become lodged in the throat or airways. Signs include sudden onset of choking and the gums may turn blue due to lack of oxygen.

**Gastrointestinal:** Foreign bodies can cause an obstruction at any point along the digestive system. Signs include inappetance, vomiting and abdominal pain.

