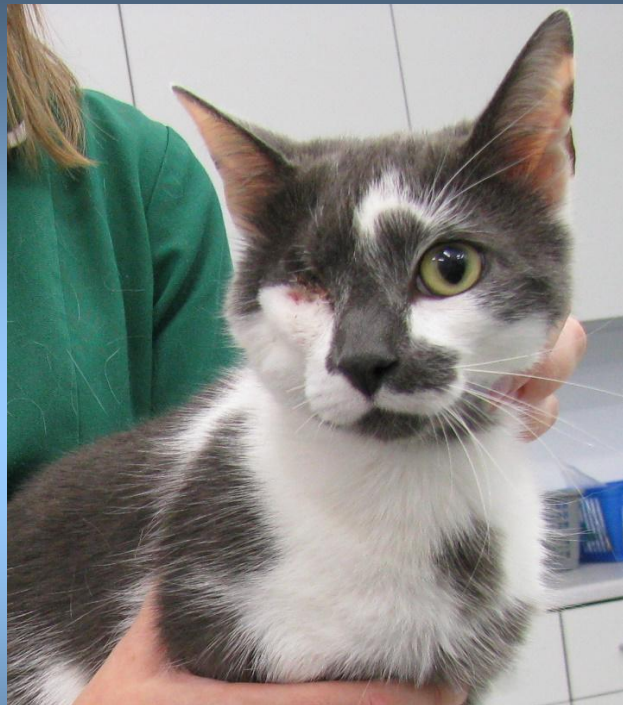



July



Smudge is a three year old male neutered cat. His owners brought him to the vets in June as his right eye was swollen. When Rebecca the vet examined Smudge it was clear that there had been some trauma to his eye and he was also in shock.

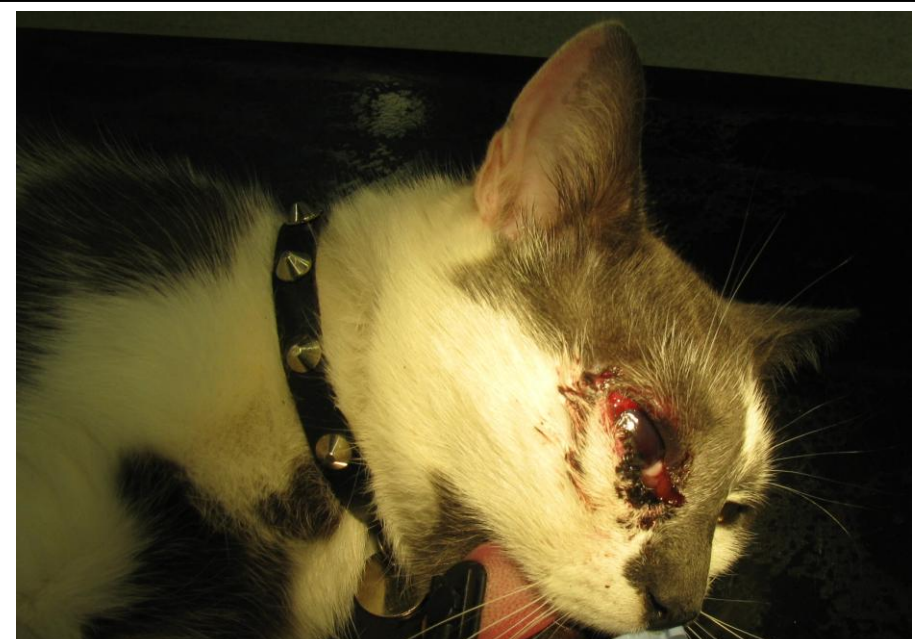The eye examination revealed significant swelling around the eye, the eyeball was black and the cornea (eye surface) was dry and damaged. There was also a darker circular area in the centre of the eye. Rebecca suspected that the cause was a penetrating trauma.



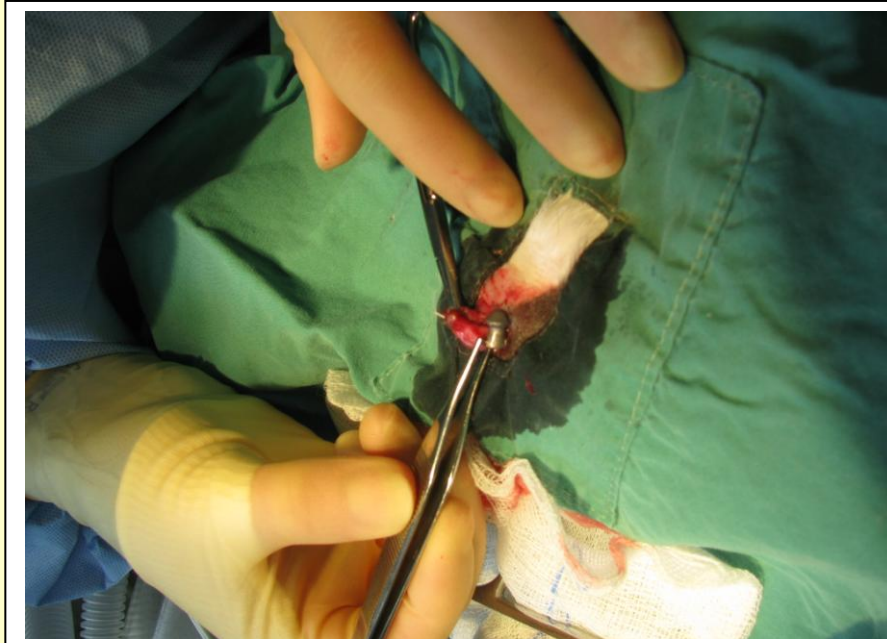
Smudge was admitted to the hospital for monitoring and pain relief and was booked in for enucleation surgery (eye removal) the following day, once he was stabilised.

Once under anaesthetic Smudge was prepared for surgery and Rebecca the vet operated to remove the eye. The trauma to the eye was caused by an air gun pellet. The pellet was removed from the eyeball during the operation.

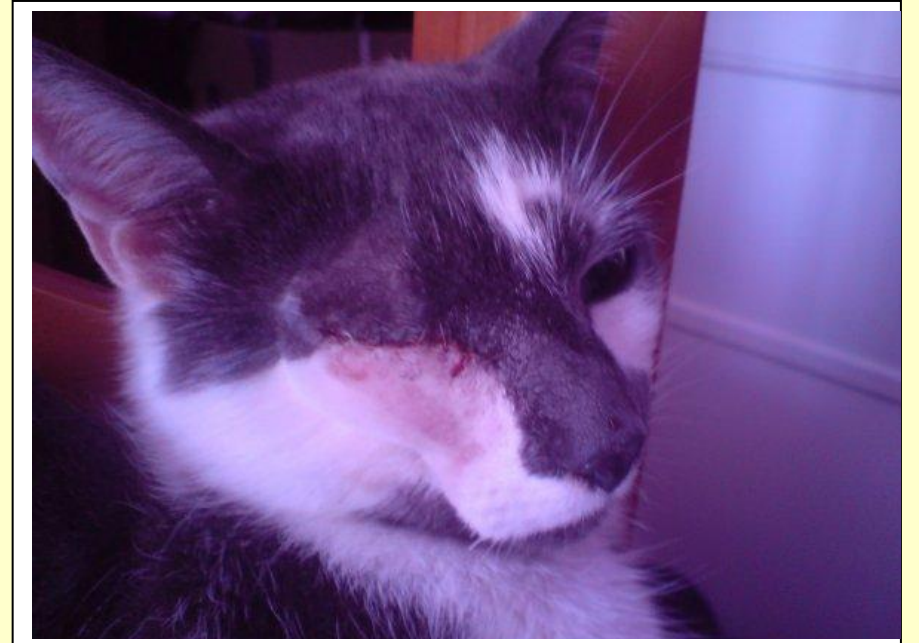
The story in pictures...



The eye before surgery



The eye and pellet are removed

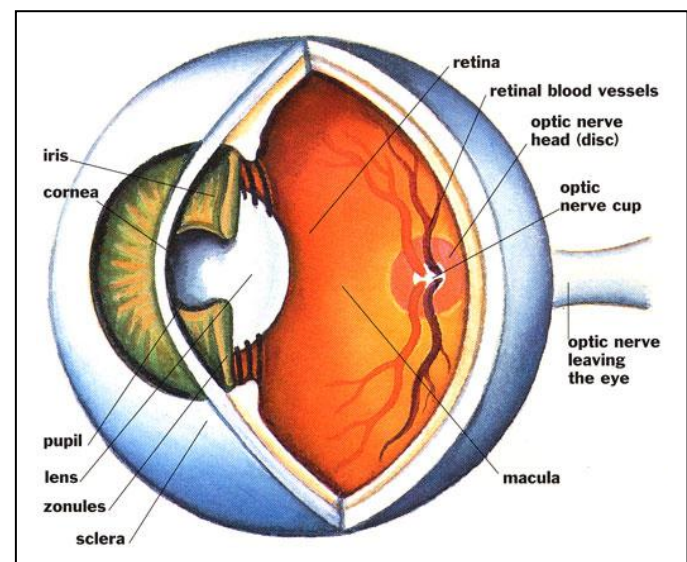


The wound begins to heal

Luckily Smudge has made a good recovery and seems to be coping well since his operation. His owners report that he is doing well and the only downside is that he has now become a little camera shy!

General Eye Health

- A healthy eye should be clear and bright.
- The area around the eyeball should be white.
- Any signs of redness, discharge, cloudiness or dullness indicate that there may be a problem.



Air gun pellets

- Unfortunately airgun pellet injuries are not uncommon.
- In June this year the RSPCA reported that they have already been inundated with more than 300 reports about air gun attacks.
- In many cases injuries caused by air gun pellets can be fatal or affect quality of life.

